

PATIENT

Sasha Burke

SPECIES

Feline

BREED

Himalayan

SEX

FS

AGE

16 years

WEIGHT

5 #

INTERPRETED BY

Remo Lobetti, BVSc,
MMedVet (Med), PhD,
Dipl. ECVIM

IMAGING PERFORMED BY

Lara Wiseman, DVM

HOSPITAL NAME

Heron Lakes Animal
Hospital

REFERRING VET

INVOICE

303090

DATE

7/2/22

PRESENTING CLINICAL SIGNS

History: Renal insufficiency, idiopathic hypercalcemia. On alendronate.

Physical Examination: N/A.

Urinalysis: N/A.

CBC: N/A.

Serum Biochemistry: Azotemia, hypercalcemia.

Radiographic Findings: N/A.

ULTRASONOGRAPHIC EXAMINATION OF THE ABDOMEN

Urinary System

Full urinary bladder with a normal thickness and appearance of the wall. Normal anechoic urine with no sediment or uroliths evident.

Normal trigone area, proximal urethra (0.2 cm), and iliac blood vessels.

Normal iliac lymph nodes. Ureters not visualized.

Left kidney – small (1.4 cm), hyperechogenic, complete loss of cortico-medullary differentiation, and an irregular capsule.

Right kidney – normal size (3.5 cm) increased echogenic appearance, loss of cortico-medullary differentiation, normal pelvis and an irregular capsule. Cortical cyst in the caudal pole.

Reproductive System

N/A.

Adrenal Glands

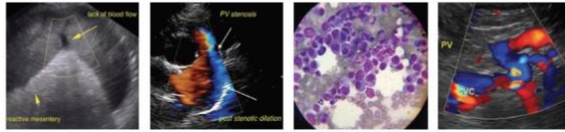
Normal shape, echogenic appearance, position, and size. Left 0.33 cm, right 0.36 cm. Pinpoint parenchymal mineralization within the right gland.

Spleen

Normal size (0.6 cm) and echogenic appearance. Smooth homogenous parenchyma, smooth curvi-linear capsule, and normal vasculature. No evidence of inflammatory, neoplastic, infarction, or infiltrative changes noted.

Liver

Normal size, echogenic appearance, and portal markings. No nodules or masses evident. Small gall bladder containing normal anechoic bile. Normal thickness and echogenic appearance of the gall bladder wall. Normal bile duct.



PATIENT

Sasha Burke

SPECIES

Feline

BREED

Himalayan

SEX

FS

AGE

16 years

WEIGHT

5 #

INTERPRETED BY

Remo Lobetti, BVSc,
MMedVet (Med), PhD,
Dipl. ECVIM

IMAGING PERFORMED BY

Lara Wiseman, DVM

HOSPITAL NAME

Heron Lakes Animal
Hospital

REFERRING VET

INVOICE

303090

DATE

7/2/22

Gastrointestinal

Normal appearance of the stomach, duodenum, small intestine, and ileo-cecal junction with no loss of layering, normal wall thickness (duodenum 0.22 cm, jejunum 0.24 cm) and peristaltic activity, and no distension of the lumen.

Pancreas

Normal size (0.6 cm) and echogenic appearance. Normal echogenic appearance of the mesentery and fat surrounding the pancreas.

Free Abdomen

No mesenteric lymphadenomegaly.
No ascites.

ULTRASONOGRAPHIC FINDINGS

Primary findings:

- Renal disease.

Secondary findings:

- Adrenal mineralization.

INTERPRETATION OF THE FINDINGS & FURTHER RECOMMENDATIONS

The appearance of the kidneys is typical for chronic kidney disease and the small left kidney is most likely from a previous episode of obstructive uropathy.

The adrenal mineralization can be considered an incidental age-related change.

Further assessment would be urinalysis, urine culture, UPC, and blood pressure.

Symptomatic management of the renal disease will be renal diet, enteric phosphate binders (as needed), and an ACE inhibitor/receptor blocker.



PATIENT

Sasha Burke

SPECIES

Feline

BREED

Himalayan

SEX

FS

AGE

16 years

WEIGHT

5 #

INTERPRETED BY

Remo Lobetti, BVSc,
 MMedVet (Med), PhD,
 Dipl. ECVIM

IMAGING PERFORMED BY

Lara Wiseman, DVM

HOSPITAL NAME

Heron Lakes Animal
 Hospital

REFERRING VET

INVOICE

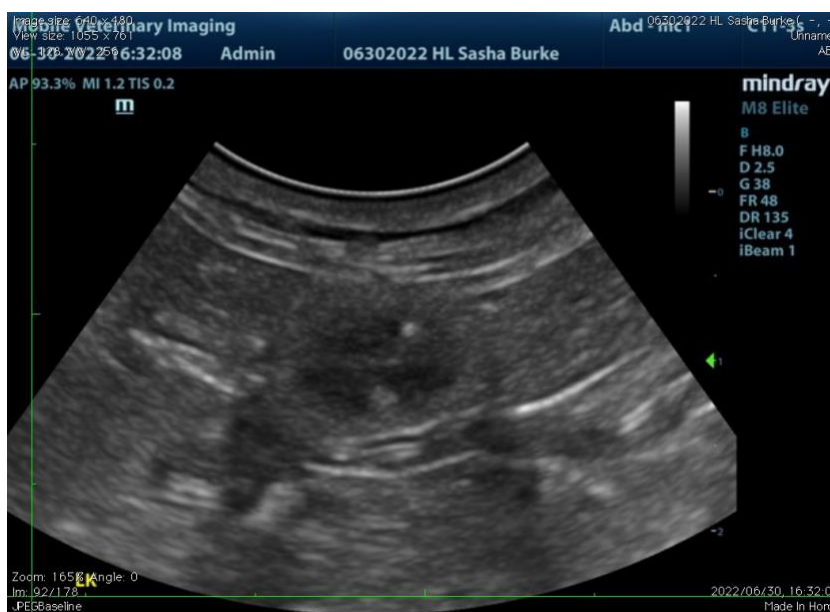303090

DATE

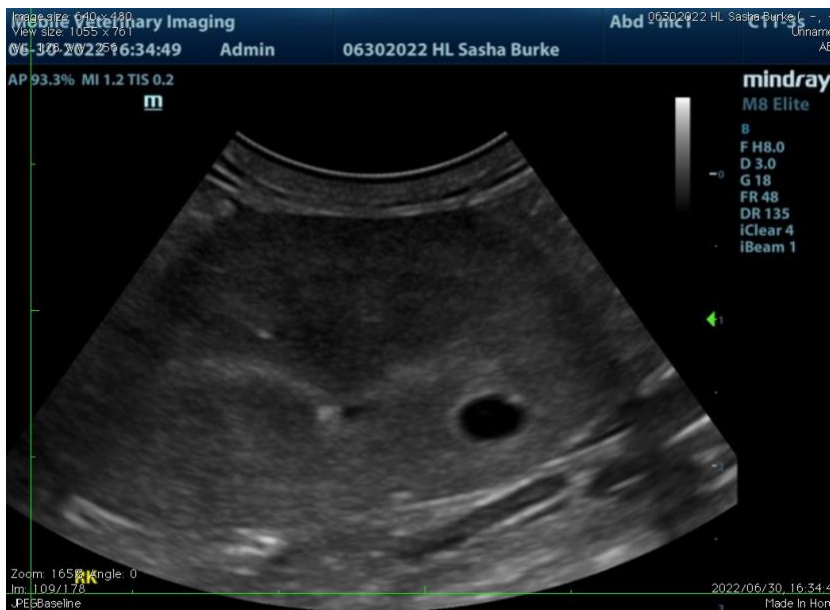7/2/22

IMAGES

Left kidney



Right kidney





PATIENT

Sasha Burke

Right adrenal gland

SPECIES

Feline

BREED

Himalayan

SEX

FS

AGE

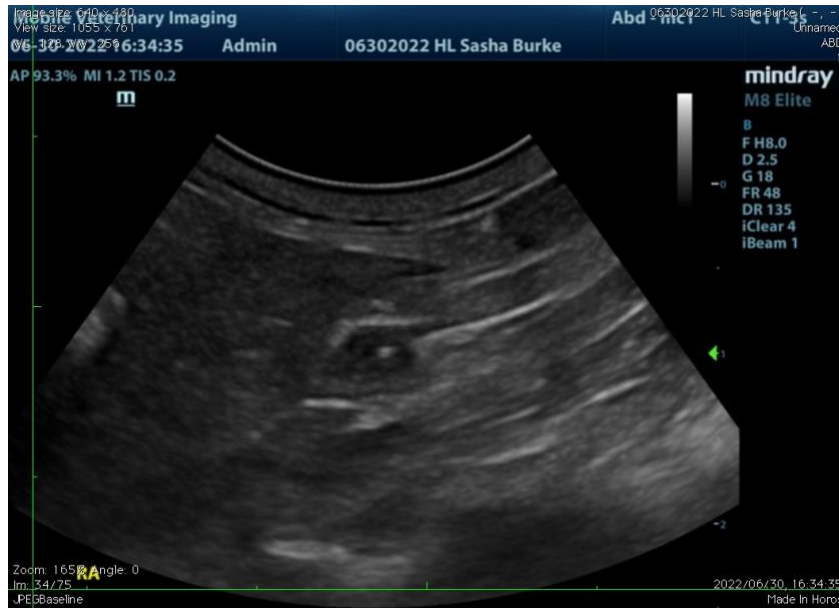16 years

WEIGHT

5 #

INTERPRETED BY

Remo Lobetti, BVSc,
MMedVet (Med), PhD,
Dipl. ECVIM



The information and recommendations provided are based on the images presented by the referring veterinarian. No evaluation can be communicated regarding pathology that was not visible in the image/video clips provided.

Thank you for this referral. If the clinical or image interpretation does not parallel your findings or if I can be of any further assistance please contact me.

Remo Lobetti, BVSc, MMedVet (Med), PhD, Dipl. ECVIM (Internal Medicine)
rlobetti@mweb.co.za

IMAGING PERFORMED BY

Lara Wiseman, DVM

HOSPITAL NAME

Heron Lakes Animal
Hospital

REFERRING VET

INVOICE

303090

DATE

7/2/22